

INCREASED OSMOTIC FRAGILITY OF RED CELLS IN DOGS
WITH ACUTE MYOCARDITIS PRODUCED BY SCORPION
(*BUTHUS TAMULUS*) VENOM

RADHA KRISHNA MURTHY KARI* AND HOSSEIN ZOLFAGHRIAN**

Departments of Physiology and Biochemistry**,*

Lokmanya Tilak Municipal Medical College,

Sion, Bombay - 400 022

(Received on November 11, 1985)

Summary : Stings from scorpions (*Buthus tamulus*) produce acute myocarditis and can result in death in children and adults. Acute myocarditis was induced in anaesthetised dogs by intravenous injection of 4 mg/kg venom (*Buthus tamulus*). Myocarditis was confirmed by ECG. Blood was collected before and 30 minutes after venom treatment and processed for osmotic fragility. An increase in osmotic fragility of red cells in addition to initial hypertension followed by hypotension were observed in venom treated animals. These results suggest that scorpion venom causes autonomic storm and the released catecholamines were responsible for acute myocarditis, changes in the blood pressure and increased osmotic fragility of red cells.

Key words : scorpion venom ECG changes *buthus tamulus*
acute myocarditis venom osmotic fragility

INTRODUCTION

Red scorpions belonging to *Buthus tamulus* are very poisonous and their stings, sometimes, produce a variety of electrocardiographic and cardiovascular changes including neurovascular deficit, acute myocarditis, pulmonary oedema, coagulation defects, disseminated intravascular coagulation and many other changes and responsible for many deaths in children and adults (4,6,18,19,20,21). Deaths due to these killer red scorpions (*Buthus tamulus*) were reported from a few pockets in few districts in Rayalaseema area of Andhra Pradesh, Alibaug of Raigad district; in and around Bombay in Maharashtra, Karnataka, Tamilnadu, Pondicherry and various other places in India (4-6, 18-21). The mechanism by which scorpion stings produce the above mentioned abnormalities and

subsequently cause death is not yet completely established. We have demonstrated earlier, cardiac sarcolemmal defects displayed by changes in $\text{Na}^+ - \text{K}^+$ ATPase, Mg^{++} ATPase and Ca^{++} ATPase activities in addition to reduction in glycogen content of atria, ventricle and liver in rabbits with acute myocarditis induced by injection of scorpion venom (*Buthus tamulus*) (2,3,17). We have suggested that the above mentioned manifestations could be due to autonomic storm (2, 3, 17). There were reports to indicate that various coagulation defects and disseminated intravascular coagulation were produced in experimental animals treated with venom (*Buthus tamulus*) (8, 10) and red cell fragmentation in association with small vessel disease (Microangiopathic) hemolytic anaemia (Thrombotic thrombocytopenic purpura) in various disorders including disseminated intravascular coagulation (DIC) (22). If epinephrine and norepinephrine are released by intense sympathetic stimulation during autonomic storm and subsequently cause acute myocarditis and DIC, then it would be logical to expect changes in the osmotic fragility of red blood cells. But changes in the osmotic fragility of the erythrocytes were not reported so far in the literature. In this study, we set out to demonstrate osmotic fragility changes in experimental animals injected with scorpion (*Buthus tamulus*) venom.

MATERIAL AND METHODS

Healthy, normal dogs of both sexes weighing 8 ± 2 kg were used in the present investigation. The dogs, after overnight fast, were anaesthetised with thiopentone (Intral sodium, 35 mg/kg) (May & Baker). Limb Lead II electrocardiogram (ECG) was recorded on 'Encardiorite polygraph', Lucknow. Mean arterial blood pressure was recorded either from carotid or femoral artery. ECG and mean arterial blood pressure were recorded continuously before and upto 30/40 min after injection of the venom. Lyophilised red scorpion venom (*Buthus tamulus*) was purchased from Haffkine Institute, Bombay, India, 4 mg/kg venom in saline was administered intravenously. Arterial blood samples were collected before and 30/40 min after venom treatment and processed for the osmotic fragility of red blood cells as described by Parpart *et al.* (14). The results were analysed according to comparison of paired data by the *t* test (difference method) (17).

RESULTS

Within a few seconds after intravenous administration of 4 mg/kg venom of red scorpions (*Buthus tamulus*), there were changes in the electrocardiogram suggestive of acute myocarditis. In addition to ECG changes shown in Fig. 1, there were sinus tachycardia, atrial and junctional extrasystoles, Multiple, multifocal and runs of ventricular fibrillation; partial and complete S.A. Block and a variety of other conduction defects, abnormal ST-T changes and infarction like pattern (All the ECG changes not shown here).

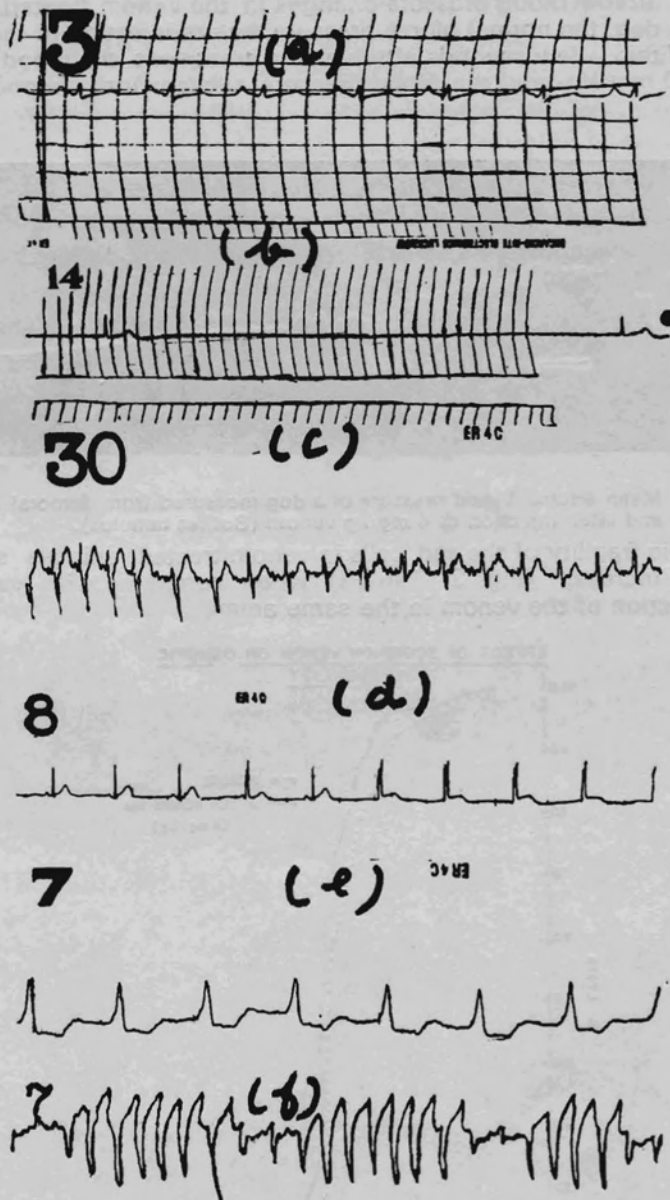


Fig. 1 (a) : Electrocardiogram showing normal sinus rhythm (Dogs), (b) : Sinus bradycardia, (c) Sinus tachycardia, (d) : Junctional rhythm, (e) ECG Strip showing broad QRS - coronary insufficiency, (f) Runs of ventricular premature contractions.

Limb Lead II ECG : Paper speed 50 mm/sec. Fig. 1 (a) ECG in dogs before venom injection. Fig. 1 (b) - (f) : ECG in dogs after injection of 4 mg/kg (Buthus tamulus) venom.

The mean arterial blood pressure changes in the venom treated animals is shown in Fig. 2. In the dog, the normal blood pressure, before injection of the venom was 100-120 mm Hg. Within a few seconds after venom treatment, the blood pressure increased to more than 250 mm Hg and the blood pressure subsequently dropped to 60-40 mm Hg within one hour.




Fig. 2 : Mean arterial blood pressure of a dog measured from femoral artery and after injection of 4 mg/kg venom (*Buthus tamulus*).

The osmotic fragility of the red cells in venom treated animals showed a statistically significant increase (Fig. 3, Table I) when compared with values from red cells taken before injection of the venom in the same animal.

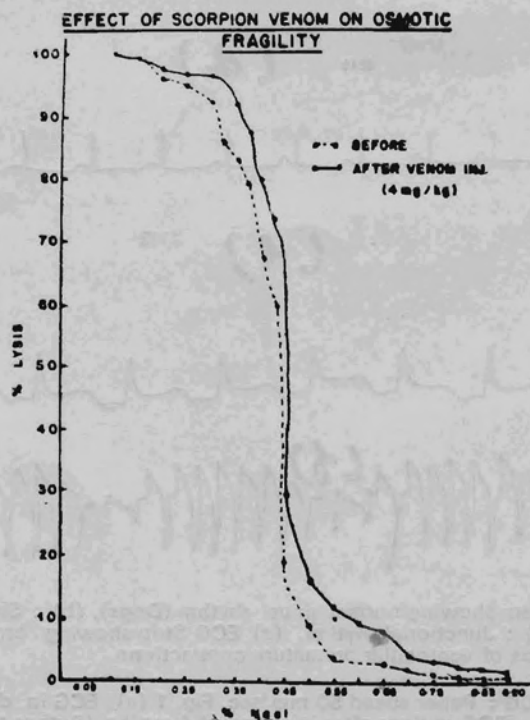


Fig. 3 : Effect of injection of scorpion venom (*Buthus tamulus*) 4 mg/kg on the osmotic fragility of red cells.

TABLE I : Effect of injection of scorpion (*Buthus tamulus*) venom on osmotic fragility of red blood cells.

% Na Cl	% Lysis		P Value <0.05 to <0.01
	Before Venom injection	After* Venom injection	
0.20	96.45	98.60	0.05
0.25	95.80	97.80	0.06
0.30	92.70	97.00	0.05
0.325	86.40	92.40	0.01
0.35	83.30	92.10	0.05
0.375	79.20	87.70	0.05
0.40	67.50	80.00	0.01
0.425	60.30	74.20	0.01
0.45	19.70	30.50	0.01
0.50	9.30	16.60	0.01
0.55	4.50	12.70	0.01
0.60	3.30	9.70	0.01
0.65	3.30	8.00	0.01
0.70	2.20	4.60	0.01
0.75	1.80	3.20	0.01
0.80	1.40	2.60	0.01
0.85	1.30	1.09	0.05

* 4 mg/kg *Buthus tamulus* scorpion venom; Each value was a mean of ten experiments.

DISCUSSION

The electrocardiographic changes in venom treated animals (Fig. 1) were indicative of acute myocarditis. These changes were in conformity with our earlier observations in rabbits treated with venom (*Buthus tamulus*) (2) and with other reports of experimental myocarditis (9, 16) and in patients with scorpion stings (6, 12, 15, 18, 20).

The changes in the mean arterial blood pressure (Fig. 2) in experimental animals treated with scorpion Venom (*Buthus tamulus*) showed :

(i) *Transient hypertension* : here the blood pressure increased to 250 mm Hg- even more than 300 mm Hg in some animals, immediately after venom injection.

(ii) *Phase of hypotension* : The pressure subsequently dropped slowly and at the

end of 30/40 min, it was 60-40 mm Hg or even less. These changes in the blood pressure could be due to release of catecholamines from stimulation of sympathetic system during autonomic storm (12). Epinephrine and norepinephrine act on alpha as well as on beta receptors (11). When alpha receptors are stimulated, they cause a raise in the mean arterial blood pressure brought about vasoconstriction. This could explain the transient hypertension (Fig. 2) which was also observed in the human victims due to scorpion stings (12). Beta receptor stimulation causes vasodilatation and consequently a fall in the blood pressure (11). Additionally, the hypotension could be due to hypocalcemia which could cause loss of tone in peripheral vasculature and due to presence of disseminated intravascular coagulation. (Results observed but not presented here).

The osmotic fragility of the red blood cells in venom injected animals (Fig. 3; Table I) increased significantly. The osmotic fragility of freshly taken red blood cells reflect their ability to take up water without lysis. The behaviour of a red cell in hypotonic saline depends on the initial ratio of surface area to volume and not on the absolute size of the cell. The ability of the normal red cell to withstand hypotonicity results from its biconcave shape to allow the cell to increase its volume by about 70% before the surface membrane is stretched further (7). Spherocytes have an increased volume to surface area ratio; their ability to take in water before stretching is very much limited and therefore are more susceptible for lysis by osmosis. The increase in osmotic fragility of the erythrocytes is thus due to its shape and is independent of the cause of the alteration of the shape of the red cell (7). In addition to the above mentioned factors, PH and temperature markedly influence the measurement of osmotic fragility (14). Hypertonic serum alters the viscosity of blood in more than complex manner and alters intracellular viscosity and affects the osmotic fragility (13).

In venom treated animals, there was sudden increase in blood sugar values (Mean 323 mg/100 ml - sometimes even more than 800 mg/100 ml) compared to 123 mg/100 ml found in the same animal before venom injection (Results observed but not presented). Similarly, there was sudden increase in the serum free fatty acids in the venom treated animals (Results observed but not presented here). The increase in the blood glucose levels and free fatty acids are well known metabolic effects of catecholamines on alpha and beta receptors (11). The increase in the blood glucose levels can inturn cause hyperosmolarity and probably could be the cause for the increased osmotic fragility of erythrocytes in venom administered animals.

There was deficiency of clotting factors like; Factor V, VI, VIII; sudden and drastic reduction of platelets, a decrease in fibrinogen and changes in coagulation profile - all suggestive of disseminated intravascular coagulation (DIC) in venom treated animals

(Results observed but not presented here). It was suggested by Wintrobe (22) that red cell fragmentation could be the result of shearing stress from the force of the arterial blood as it moves past red cells that are attached to endothelial projections or have partially penetrated endothelium. This was confirmed by parallel observations made in rabbits receiving catecholamine infusions (Mckay D.G. *et al.* 1969, *Am. J. Pathol.*, Vol 56; P. 177, quoted from 15). In the present investigation, there was sufficient to suggest that there was disseminated intravascular coagulation (DIC) in venom treated animals. The resultant defibrination could be due to increased quantities of catecholamines released by stimulation of sympathetic system during autonomic storm after administration of the scorpion (*Buthus tamulus*). Though the catecholamines were not measured in the present study, the changes in mean arterial blood pressure were (Fig. 2) indicative of increased release of catecholamines.

It is suggested that stings due to killer red scorpions (*Buthus tamulus*) are very serious and should be treated as medical emergency and a heroic treatment is a must to reverse the fatal outcome.

ACKNOWLEDGEMENTS

The authors like to thank Prof. N.A. Dabholkar, Prof, F. R. Billimoria and the Dean, L.T.M. Medical College for giving facilities to conduct these experiments. This work was financed by Department of Atomic Energy, Government of India and L.T.M.M.C. and L.T.M.G.H. Staff and Research Society.

REFERENCES

1. Anita, K. Bahn. In : Basic medical statistics., Grune & Stratton, New York, *Medical Inc.*, P. 145-156, 1972.
2. Balasubramaniam, P. and K. Radhakrishnamurthy. Abnormal cardiovascular and electrocardiographic profiles and cardiac glycogen content in rabbits injected with scorpion venom. *Ind. J. Physiol. Pharmac.*, 25:351-354, 1981.
3. Balasubramaniam, P. and K. Radhakrishnamurthy. Liver glycogen depletion in acute myocarditis produced by scorpion venom (*Buthus tamulus*). *Ind. Heart J.*, 36:101-103, 1984.
4. Bhaskara Reddy, D. and G. Suvarnakumari. Fatal cases of scorpion sting. Autopsy study of 7 cases. *Clinician*, 36:94-96, 1972.
5. Bichile, L.S., K P. Kuloor, S.R. Gupta and S.A. Nanivadekar. Fulminant pulmonary oedema following myocarditis due to scorpion sting *Ind. Practitioner*, 37:283-285, 1984.
6. Bisarya, B.N., J.P. Vasvada, A. Bhatt, P.N.R. Nair and V.K. Sharma Hemiplegia and myocarditis following scorpion bite. *Indian Heart J.*, 29:97-100, 1977.
7. Dacie, J.V. and S.M. Lewis. In : Practical haematology, The English language book society and Churchill Livingstone, 5th edition. P. 202, 1982.

8. Devi, C.S., C. Narayanareddy, S. Lakshmidevi, Y.R. Subramaniam, G. Suvarnakumari, P. Murthy and C.R.R.M. Reddy. Defibrination syndrome due to scorpion venom poisoning. *Brit. Med. J.*, 1:345-347, 1970.
9. Gajalakshmi, B.S., N. Ramaswamy, C. Thigarajan and G.M. Yaha. Certain observations in electrocardiogram and enzyme variations in dogs following scorpion venom injection. *Ind. J. Physiol. Pharmac.*, 22:397-400, 1978.
10. Gajalakshmi, B.S. Coagulation studies following scorpion venom injection in animals. *Ind. J. Med. Res.*, 76:337-341, 1982.
11. Goodman, L.S. and A. Gilman. The pharmacological basis of therapeutics. 5th edition. Macmillan Pub. Co. Inc., New York. P. 477-573, 1975.
12. Gueron, M. and S. Weizman. Catecholamines and myocardial damage in scorpion stings. *Am. Heart J.*, 75:715-717, 1968.
13. Murphy, J.R. The influence of pH and temperature of some physical properties of normal erythrocytes and erythrocytes from patients with hereditary spherocytosis. *J. Lab. & Clin. Med.*, 69:758-775, 1967.
14. Parpart, A.K., P.B. Lorenz, E.R. Parpart, J.R. Gregg and A.M. Chase. The osmotic resistance (Fragility) of human red cells. *J. Clin. Invest.*, 26:636-640, 1947.
15. Poon King, T. Myocarditis from scorpion sting. *Brit. Med. J.*, 1:374-377, 1963.
16. Purushotham Rao, G., B.K. Premlata, H. Venkatakrisna Bhatt and P.S.R.K. Haranath. Cardiac and behavioral effects of scorpion venom in experimental animals. *Ind. Ped.*, 6:95-99, 1969.
17. Radhakrishnamurthy, K. Investigations of cardiac sarcolemmal ATPase activity in rabbits with acute myocarditis produced by scorpion venom (*Buthus tamulus*). *Jpn. Heart J.*, 23:835-842, 1982.
18. Rajarajeswari, G., S. Sivaprakasam and J. Viswanathan. Morbidity and mortality pattern in scorpion stings. *J. Ind. Med. Assn.*, 73:123-126, 1979.
19. Reddy, C.R.R.M., G. Suvarnakumari, C.S. Devi and C.N. Reddy. Pathology of scorpion venom poisoning. *J. Trop. Med. Hyg.*, 75:98-100, 1972.
20. Santhanakrishnan, B.R., G. Ranganathan, P. Ananthasubramaniam and V.B. Raju. Cardiovascular manifestation of scorpion sting in children. *Ind. Ped.*, 14:353-357, 1977.
21. Singh, D.S., D.B. Bisht, G. Sukumar and K. Muralidhar. Scorpion sting in adult South Indians at Pondicherry. *J. Ind. Med. Assn.*, 72:234-237, 1979.
22. Wintrobe M.M. In: *Clinical Haematology*. Ed. Lea & Febiger, Philadelphia, P. 734 & 1211, 1974.